High-Frequency Ultrasound Examination in the Diagnosis of Skin Cancer

Robert L. Bard, MD

KEYWORDS

• Malignant melanoma • Nonmelanoma skin cancer • Ultrasound guidance • 3D Doppler sonography • Image guided treatment • Sentinel node biopsy

KEY POINTS

- Sonographic tumor depth evaluation has 99% histopathologic correlation.
- Melanoma metastatic potential is proportional to vessel density of neovascularity as measured by Doppler histogram analysis.
- Intransit and nonpalpable locoregional metastases can be detected with 3-dimensional image reconstruction.
- Three-dimensional mapping of nerves and arteries optimizes preoperative planning.
- Image-guided biopsy and treatments are cost effective and reduce morbidity.

INTRODUCTION

Today's health conscious society means adults routinely seek reassurance about suspicious skin lesions. Diagnostic ultrasound examinations can accurately and rapidly differentiate between epidermal, subdermal, and subcutaneous tissues in real time. This procedure may help to identify lesions invisible to the spatially restricted human eye. The high resolution and low cost of today's ultrasonographic equipment allow this modality to be used readily in an outpatient office setting.

The accuracy of ultrasonography in the epidermis, dermis, and subcutaneous tissues is both operator and equipment dependent. Standard 2-dimensional linear sonograms at 40 to 100 MHz image the epidermis. Probes using 15-to 22-MHz image the epidermis and dermis, including the adjacent tissues 1 to 2 cm deep to the basal dermal layer. Real time 3-dimensional (3D/4D) probes at 16 to 20 MHz using broadband technologies provide high resolution of these structures to a 4- to 7-cm depth in seconds. Today's high-resolution equipment is widely available as imaging technology.

EVOLUTION OF DIAGNOSTIC ULTRASOUND IMAGING

Diagnostic ultrasound examination has been used on the skin and subcutaneous tissues for more than 25 years in Europe and Japan. The technology has evolved from its original use in cyst detection with B scans[1] to its present use for cancer detection using 3D imaging to detect in-transit metastases. Additionally, in vivo flow velocity analysis can now be used to detect melanoma vessel density and analyze tumor microvascularity at 10 micron imaging.[2] Experimental photo and laser acoustic technologies are also currently being studied in animal research. This article provides a basic overview of skin imaging applications. A more in-depth review of dermal ultrasonography may be found elsewhere in the literature.[3]

Bard Cancer Center, 121 East 60th Street, New York, NY 10022, USA
E-mail address: rbard@cancerscan.com

Dermatol Clin 35 (2017) 505–511
http://dx.doi.org/10.1016/j.det.2017.06.011

HOW THE EXAMINATION IS PERFORMED

The application of ultrasonography depends on the area examined and equipment needed for specific diagnosis. All probes require gel contact with the skin and scan duration is typically proportional to the type of probe and examiner's experience. Real-time imaging by a trained physician allows simultaneous picture generation and interpretation to occur within minutes. Routine B scan units require operator-dependent probe motion in 2 planes to obtain orthogonal images. The 3D imaging systems are operator independent because the probe is held steady over the area of interest and electronics scan a 4 × 4-cm area in 6 seconds. Patient motion rarely degrades the images owing to the rapid scan rate. Transducer size is matched to scan areas or can be focused to limited facial regions such as the nose. Three-dimensional imaging of ear and nose cartilage is also available with specialized probes. Lesions can be echogenic or hyperechoic (many internal echoes), such as hemorrhagic areas, echo poor or hypoechoic (few internal echoes), and echo free (no internal echoes), which are usually found in fluid, such as cysts.

ULTRASOUND EVALUATION OF DERMAL LESIONS

The incidence of melanoma and nonmelanoma skin cancer are both increasing. Earlier detection discovers smaller lesions where focal nonsurgical treatment may be preferred to standard operative techniques, which may limit potential long-term and postoperative side effects. Ultrasound examination permits rapid measurement of skin thickness, fat tissue depth, and fascial integrity. Medical imaging maps arteries, veins, and nerves, which provides preoperative landmarks that can reduce the risk of postoperative bleeding and nerve damage (**Fig. 1**). Image-guided treatment may also decrease the risk of postoperative disfigurement. Interval scans may also be used to track and assess lesions with low aggressive potential.

DIAGNOSTIC APPLICATIONS FOR NONMELANOMA SKIN CANCER

Clinical diagnosis is the primary modality used to identify nonmelanoma skin cancer; however, visual diagnosis alone cannot determine tumor depth. Imaging allows preoperative mapping of a lesion, which may alert the surgeon to the depth or subclinical extent of a lesion. This information allows surgical planning, which can help to limit the number of stages required and allow for preoperative planning to identify optimal techniques for surgical closure. The presence of coexisting benign disease, such as seborrheic hyperplasia or peritumor inflammatory reaction, may falsely lead to a wider excision or inaccurate biopsy conclusions.

Of basal cell carcinomas, 85% develop in the head and neck, showing a predilection for thin skin, such as the nose, lips, or eyelids. The various shaped probe constructions allow diagnostic evaluation of nearly all locations including external ear compartments (**Fig. 2**). Although most basal cell carcinomas lesions appear as well-defined, oval, echo-poor masses, lesions that may have a higher aggressive potential may also appear as hyperechoic spots.

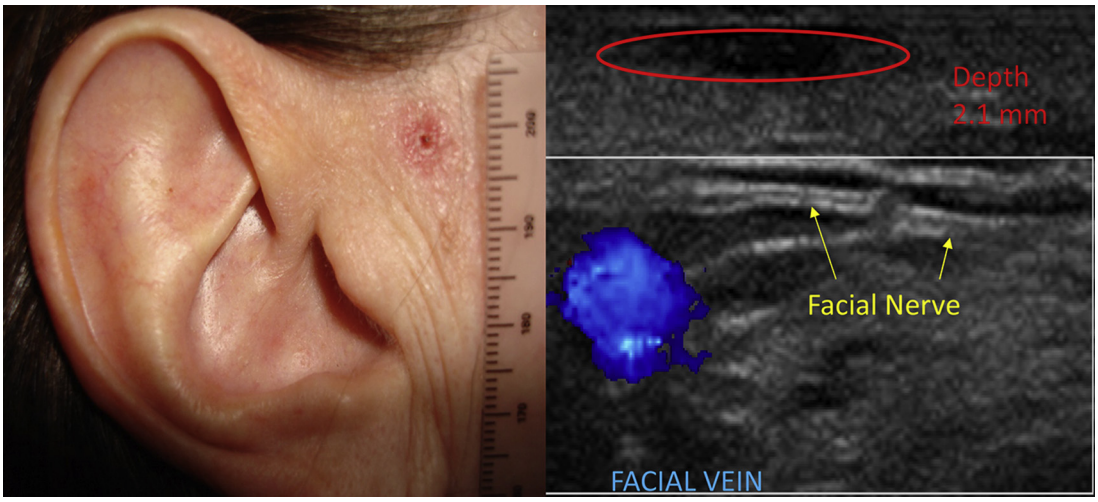

Fig. 1. Basal cell carcinoma echo-poor lesion (*circle*) 2.1 mm deep located 5 mm from the facial nerve (*arrows*) and 7 mm from temporal vein (*blue*).

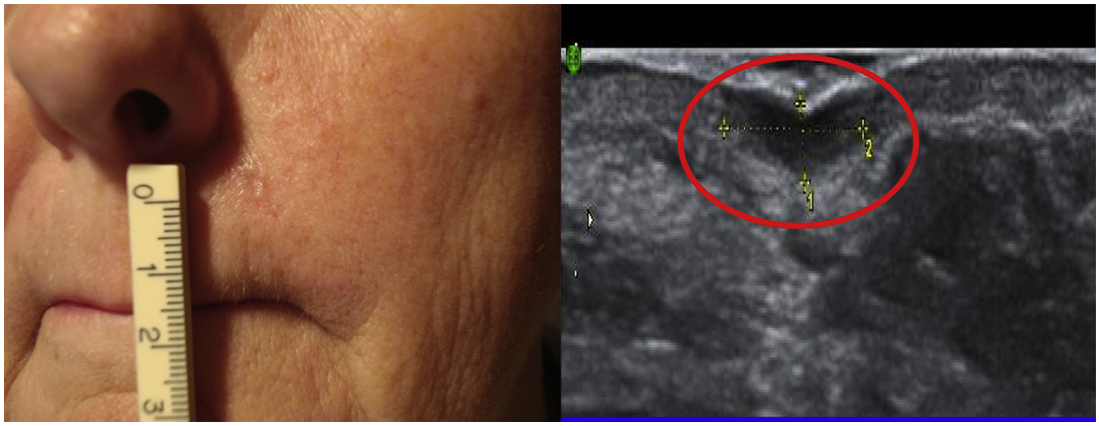

Fig. 2. Basal cell carcinoma (*red circle*) echo-poor mass in nasolabial groove imaged with small transducer to improve contact depth measurement of 1.5 mm.

Identification of these foci is useful because neovascularity is less than that in other cancers.[4] Indeed, the appearance of tortuous vessels suggests squamous cell carcinoma, Merkel cell carcinoma, or metastatic tumor. The depth correlation between ultrasonography and histology is excellent,[5] which allows for better preoperative planning (**Fig. 3**).

Squamous cell carcinoma presents as a hypoechoic lesion with irregular borders. Because the thickness or depth of invasion is an important predictor of metastases, the lesion should be followed along its entire course. Extra care is taken to find locoregional metastases and ultrasound examination of the liver and regional nodes may be performed simultaneously. The vascular pattern is increased diffusely throughout the entire mass as opposed to basal cell carcinomas, where the neovascularity is less prominent and often at the bottom of the lesion. Vascular mapping for major feeders with 3D ultrasonography is useful owing to the possibility of widespread penetration of the lesion (**Fig. 4**).

UNCOMMON DERMAL MALIGNANCIES

Dermatofibrosarcoma protuberans demonstrates a hypoechoic pattern that propagates horizontally and may project into the fascial or muscular layers. Merkel cell carcinoma presents as an echo-poor, ill-defined area. Lymphoma cell varieties have mixed echo patterns (the echo poor-ones may be mistaken for fluid collections) and variable vascularity. Increased neovascularity is noted in cases with patients on immunosuppressants. Sarcomas are echo poor, except where

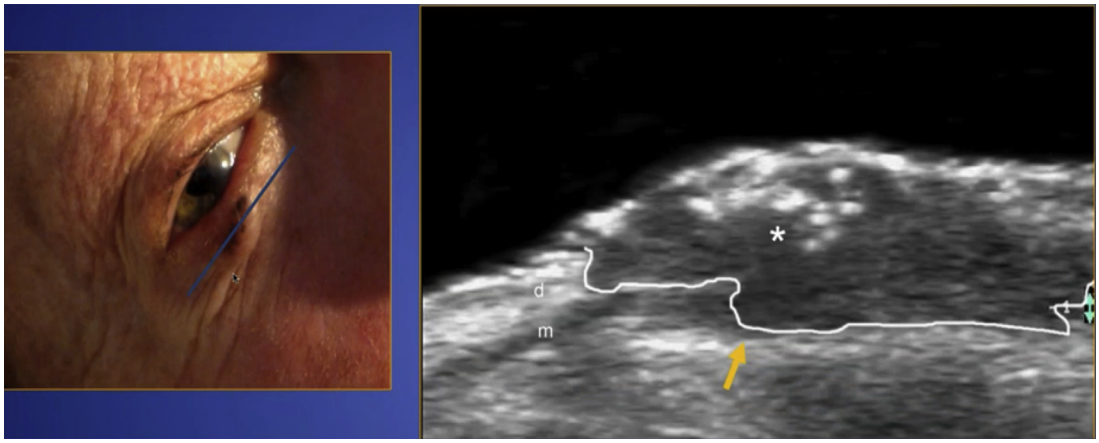

Fig. 3. Basal cell carcinoma echo-poor mass with involvement of the orbicularis oculus muscle (m). Tumor (*asterisk*) echogenic foci signifies increased aggression and invades the dermis (d) and muscle layer (m) into the fat (*arrow*).

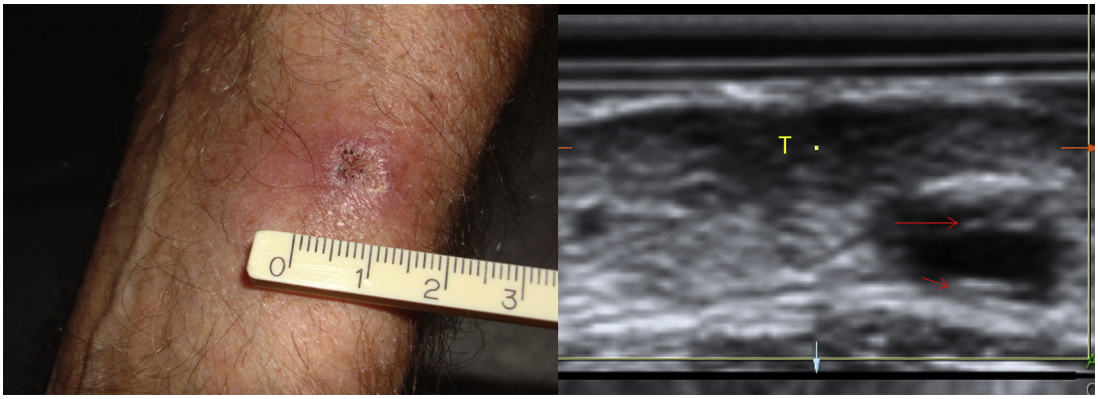

Fig. 4. Squamous cell cancer (T) echo-poor mass 2 mm from vein. Note the venous valves as linear white structures (*red arrows*).

internal necrosis and hemorrhage occur. The presence of intact fat–fascial boundaries portends a better prognosis.

STAGING OF NONMELANOMA SKIN CANCER

Ultrasound imaging accurately measures tumor diameter in all axes, blood flow within and adjacent to the lesion, and the presence of deep layer involvement, including nonpalpable satellites in subcutaneous locations. This staging additionally has the potential to streamline Mohs surgery and provides 1-stage treatment, decreasing the recurrence rate and improving cosmetic outcome.

MELANOCYTIC LESIONS

Ultrasound screening is well-tolerated and can be highly accurate in the diagnosis of melanocytic skin lesions. The finding of a subclinical metastatic focus near the lesion (provided by newer ultrasound and spectral technologies) may facilitate the physician's decision to pursue further histologic evaluation. Additionally, advanced knowledge of lesion borders, volume, and depth from the skin surfaces could allow for tissue conservation and improved aesthetic outcomes.

PRIMARY CUTANEOUS MALIGNANT MELANOMA

Melanoma appears as a fusiform, well-defined, echo-poor lesion. At frequencies below 14 MHz, it may appear echo free in a similar fashion to lymphoma owing to the densely packed homogeneous cell architecture (**Fig. 5**). Melanomas less than 0.4 mm often give a false-negative examination because the peritumor inflammatory infiltrate may falsely increase the imaged tumor depth.[6,7] Primary cutaneous melanomas commonly appear hypervascular.[8–11] Contrast-enhanced ultrasound imaging is the optimal modality to observe arteriovenous shunting and measure Doppler peak systolic and resistance indices. Assessment of angiogenesis also correlates with metastatic potential.[1,12,13] Flow signals can be seen at the tumor base and, less frequently, in the lateral margins. This helps to differentiate melanoma from verruca, where the vascular tree is located centrally and extends to the surface.[14–16] Histogram vessel density analysis has not been reported in the dermal literature, but it is widely used in the evaluation of other malignant tumors.[17–23]

STAGING OF MALIGNANT MELANOMA

Primary melanoma vascular lesions generally have locoregional vascular metastases, revealing a tissue signature of similar neovascular findings to the original cutaneous disease. Satellite lesions and in-transit metastases are definable within the 4×4-cm area imaged by the 3D dataset with specific appearance described as a "tail sign" (**Fig. 6**). Histogram analysis of 99 metastatic foci including 18 melanomas presented at the 2015 Journees Francaises de Radiologie and at the 2016 International Society of Dermatologic Surgery noted vessel density correlated with the Breslow classification.

IMAGE-GUIDED BIOPSY

New computer programs use nanotechnology and cybernetic modalities for image-guided biopsy and treatment options. Using 3D Doppler ultrasonography, the physician manually targets the area of highest tumor neovascularity. This is critical because only part of a mass may be cancerous and missed on nontargeted punch biopsies. The fusion of MRI with ultrasound imaging

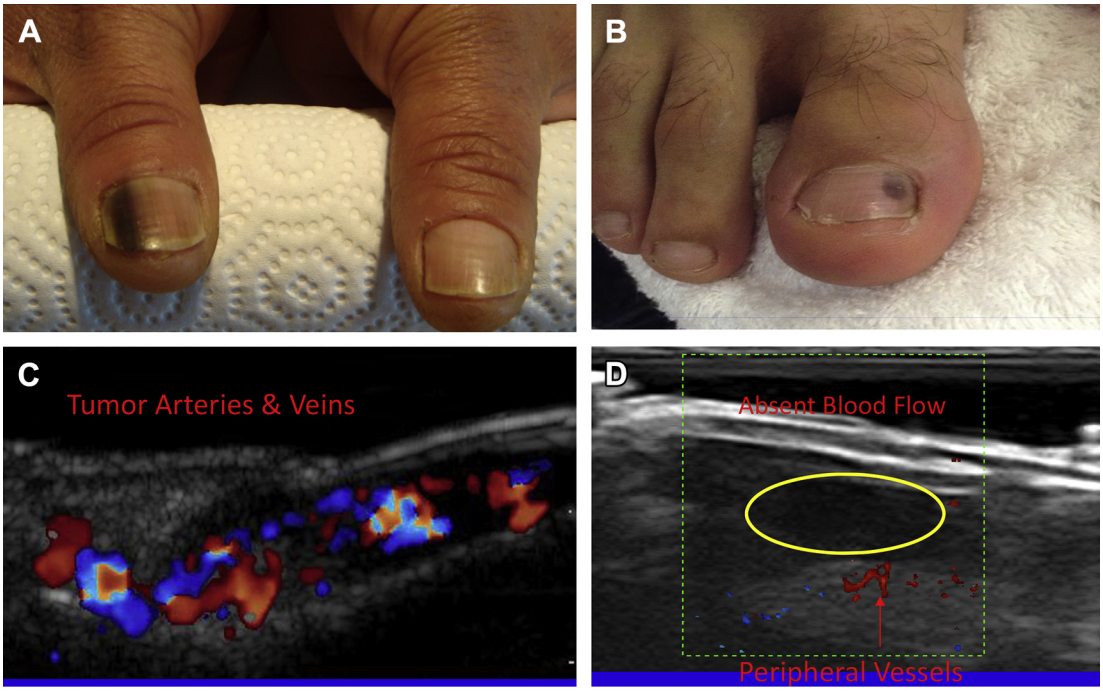

Fig. 5. Pigmented lesions. (*A*) Vertical area thumbnail. (*C*) Doppler imaging showing arteriovenous fistulae below nail plate characteristic of melanoma. (*B*) Vertical area toe nail of soccer player. A<B<C (*D*) Doppler imaging showing avascular region consistent with hematoma (*dotted square* indicates field of blood flow imaged).

permits image-guided biopsies sparing adjacent neurovascular bundles, allowing customized ultrasound-guided biopsies to be performed under local anesthesia.

MELANOMA-RELATED SENTINEL LYMPH NODE BIOPSY

Tumor depth guides appropriate performance of regional nodal lymph node biopsy. Current guidelines suggest that a thickness of greater than 1 mm reinforces the operative decision for sentinel lymph node biopsy. Ultrasound imaging has the potential to identify sentinel node involvement beyond micrometastases.

COMPARISON WITH OTHER NONINVASIVE TECHNOLOGIES

In some clinical situations, ultrasound imaging compared favorably with other technologies. Multispectral imaging, optical coherence

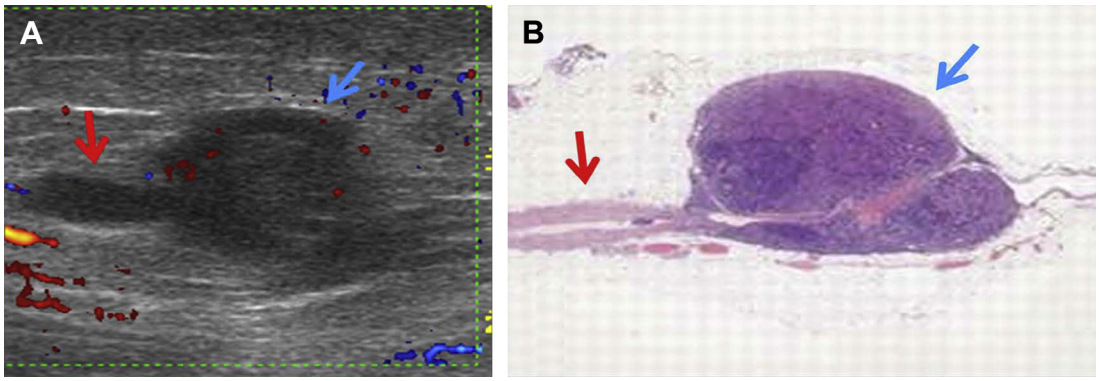

Fig. 6. Metastatic melanoma to lymph node. (*A*) Abnormal subcutaneous echo-poor lymph node with echo-poor extension indicated tumor in the lymphatic channel. (*B*) Pathology specimen—lymph duct (*red arrow*) node (*blue arrow*).

tomography, Reflectance Confocal Microscopy, and dermoscopy are limited by depth of penetration, operator experience, availability, and diagnostic specificity.[24] Spectroscopy using electrical impedance, Raman analysis, and proteomic mass are newer procedures currently under investigation (reviewed in this issue). Higher resolution technologies such as photoacoustic imaging and multiphoton analysis used in research laboratories are not clinically available yet, but promise unparalleled imaging of the epidermal layers and tumor vessel oxygenation measurements.

FUTURE DEVELOPMENTS

Advances in ultrasound imaging include ultrahigh frequency probes from 20 to 100 MHz providing image resolution up to 30 microns and ultrasound contrast agents allowing real-time imaging of tumor neovascularity. Histopathology has demonstrated tumors not only vary markedly over their surface volume in appearance, but have variations in microvasculature affecting aggression potential. Tumor immunohistochemical markers show a strong correlation with tumor neovascularity with subharmonic contrast ultrasound imaging.[25] Three-dimensional ultrasound imaging quantifies vessel density in different quadrants improving targeting. Contrast bubble imaging is not yet approved by the US Food and Drug Administration for the skin, but may add new dimensions in assessment of treatment by monitoring quantitative changes in tumor vessel density.

SUMMARY

Portable-high resolution ultrasonography now available distinguishes vascular lesions from nonvascular masses. Tumor depth can be measured quickly and locoregional metastases can be accurately observed. Additionally, preoperative imaging may identify cartilage or neural invasion and shorten Mohs surgery and complementary treatments. As ultrasound becomes more mainstream in skin cancer diagnosis and management, a better understanding of the benefits of this technology may occur.

REFERENCES

1. Lassau N, Spatz A, Avril MF, et al. Value of high frequency US for preoperative assessment of skin tumors. Radiographics 1997;17:1559–65.
2. Errico J, Pierre S, Pezet Y, et al. Ultrafast ultrasound localization microscopy for deep super-resolution vascular imaging. Nature 2015;527:499–502.
3. Wortsman X, Holm EA, Wulf HC, et al. Real time spatial compound imaging of the skin. Skin Res Technol 2004;10:23–31.
4. Wortsman X. Sonography of facial cutaneous basal cell carcinoma. J Ultrasound Med 2013; 32:567–72.
5. Bobadilla F, Wortsman X, Munoz C, et al. Pre-surgical high resolution ultrasound of facial basal cell carcinoma: correlation with histology. Cancer Imaging 2008;8:163–72.
6. Lassau N, Chami L, Chebil M, et al. Dynamic contrast enhanced ultrasonography and anti-angiogenic treatments. Discover Med 2011;11:18–24.
7. Restreppo CS, Ocazionex D. Kaposi's sarcoma: imaging overview. Semin Ultrasound CT MR 2011;32: 456–69.
8. Tacke J, Haagen G, Horstein O, et al. Clinical relevance of sonographically derived tumour thickness in malignant melanoma. Br J Dermatol 1995;132: 209–14.
9. Guitera P, Li PX, Crotty K, et al. Melanoma histological Breslow thickness predicted by 75MHz sonography. Br J Dermatol 2008;159:364–9.
10. Hoffman K, Jung J, el Gammal S, et al. Malignant melanoma in 20 MHz B-scan sonography. Dermatology 1992;185:49–55.
11. Catalano O, Siani A. Cutaneous melanoma: role of ultrasound in the assessment of locoregional spread. Curr Probl Diagn Radiol 2010;39:30–6.
12. Lassau N, Mercier S, Koscielny S, et al. Prognostic value of high frequency sonography and color Doppler for preoperative assessment of melanomas. Am J Roentgenol 1999;172:457–61.
13. Lassau N, Koscielny S, Avril MF, et al. Prognostic value of angiogenesis evaluated by high frequency and Doppler ultrasound for preoperative assessment of melanomas. Am J Roentgenol 2002;178: 1547–51.
14. Nicolaidou E, Mikrova A, Antoniou C, et al. Advances in Merkel cell carcinoma pathogenesis and management. Br J Dermatol 2012;166:16–21.
15. Pileri A Jr, Patrizi A, Agostinelli C, et al. Primary cutaneous lymphomas: a reprisal. Semin Diagn Pathol 2011;28:214–33.
16. Galper SL, Smith BD, Wilson LD. Diagnosis and management of mycosis fungoides. Oncology (Williston Park) 2010;24:491–501.
17. Bard R. Advances in image guided oncologic treatment. J Targ Ther Cancer 2016;1:52–6.
18. Music MM, Hertl K, Kadivec M, et al. Preoperative ultrasound with 15 MHz probe reliably differentiates between melanoma thicker and thinner than 1 mm. J Eur Acad Dermatol Venereol 2010;24: 1105–8.
19. Rossi CR, Mocellin S, Scagnet B, et al. The role of preoperative ultrasound in detecting lymph-node metastases before sentinel node

biopsy in patients with melanoma. J Surg Oncol 2003;83:80–4.
20. Van Rijk MC, Teertstra HJ, Peterse JL, et al. Ultrasonography and fine needle aspiration cytology in the preoperative evaluation of patients with melanoma eligible for sentinel node biopsy. Ann Surg Oncol 2006;13:1511–6.
21. Ulrich J, van Akooi AC, Eggermont AM, et al. New developments in melanoma: utility of ultrasound imaging (initial staging). Expert Rev Anticancer Ther 2011;11:1693–701.
22. Voit C, van Akooi AC, Schafer G, et al. Ultrasound morphology criteria predict metastatic disease of the sentinel nodes in patients with melanoma. J Clin Oncol 2010;28:847–52.
23. Catalano O. Critical analysis of the ultrasound criteria for diagnosing lymph node metastases in patients with cutaneous melanoma. J Ultrasound Med 2011;30:547–60.
24. Que SK, Grant-Kels JM, Longo C, et al. Basics of confocal microscopy and the complexity of diagnosing skin tumors. Dermatol Clin 2016;34:367–75.
25. Gupta A, Forsberg M, Dulin K, et al. Comparing quantitate immunohistochemical markers of angiogenesis to contrast enhanced subharmonic imaging. J Ultrasound Med 2016;35:1839–47.